

RESEARCH ARTICLE

Sourcing high tissue quality brains from deceased wild primates with known socio-ecology

Tobias Gräßle^{1,2} | Catherine Crockford^{3,4,5} | Cornelius Eichner⁶ |
 Cédric Girard-Buttoz^{3,4,5} | Carsten Jäger^{7,8} | Evgeniya Kirilina^{7,9} | Ilona Lipp⁷ |
 Ariane Düx^{1,2} | Luke Edwards⁷ | Anna Jauch⁷ | Kathrin S. Kopp¹⁰ |
 Michael Paquette⁷ | Kerrin Pine⁷ | EBC Consortium | Daniel B. M. Haun¹⁰ |
 Richard McElreath⁴ | Alfred Anwander⁶ | Philipp Gunz¹¹ | Markus Morawski^{7,8} |
 Angela D. Friederici⁶ | Nikolaus Weiskopf^{7,12} | Fabian H. Leendertz^{1,2} |
 Roman M. Wittig^{3,4,5}

¹Epidemiology of highly pathogenic microorganisms, Robert Koch-Institute, Berlin, Germany; ²Helmholtz Institute for One Health, Greifswald, Germany; ³Ape Social Mind Lab, Institute of Cognitive Science Marc Jeannerod, UMR 5229, CNRS, Lyon, France; ⁴Department of Human Behavior, Ecology and Culture, Max Planck Institute for Evolutionary Anthropology, Leipzig, Germany; ⁵Taï Chimpanzee Project, Centre Suisse de Recherches Scientifiques en Côte d'Ivoire, Abidjan, Ivory Coast; ⁶Department of Neuropsychology, Max Planck Institute for Human Cognitive and Brain Sciences, Leipzig, Germany; ⁷Department of Neurophysics, Max Planck Institute for Human Cognitive and Brain Sciences, Leipzig, Germany; ⁸Paul Flechsig Institute - Center of Neuropathology and Brain Research, Faculty of Medicine, Universität Leipzig, Germany; ⁹Center for Cognitive Neuroscience Berlin, Freie Universität Berlin, Berlin, Germany; ¹⁰Department of Comparative Cultural Psychology, Max Planck Institute for Evolutionary Anthropology, Leipzig, Germany; ¹¹Department of Human Evolution, Max Planck Institute for Evolutionary Anthropology, Leipzig, Germany and ¹²Felix Bloch Institute for Solid State Physics, Faculty of Physics and Earth Sciences, Leipzig University, Leipzig, Germany

Correspondence

Tobias Gräßle
 Email: tobias.c.graessle@gmail.com

Catherine Crockford
 Email: crockford@eva.mpg.de

Funding information

Bundesministerium für Bildung und Forschung, Grant/Award Number: 01EW1711A & B; European Research Council under the European Union's Seventh Framework Programme, Grant/Award Number: FP7/2007-2013/ERC grant agreement n° 616905; European Union's Horizon 2020 Research and Innovation Programme, Grant/Award Number: 681094; Max-Planck-Gesellschaft; Max Planck Society

Handling Editor: Thibaud Gruber

Abstract

1. The selection pressures that drove dramatic encephalisation processes through the mammal lineage remain elusive, as does knowledge of brain structure reorganisation through this process. In particular, considerable structural brain changes are present across the primate lineage, culminating in the complex human brain that allows for unique behaviours such as language and sophisticated tool use. To understand this evolution, a diverse sample set of humans' closest relatives with varying socio-ecologies is needed. However, current brain banks predominantly curate brains from primates that died in zoological gardens. We try to address this gap by establishing a field pipeline mitigating the challenges associated with brain extractions of wild primates in their natural habitat.
2. The success of our approach is demonstrated by our ability to acquire a novel brain sample of deceased primates with highly variable socio-ecological exposure

Consortium full member list at the end of the paper

Tobias Gräßle and Catherine Crockford joint first author

Fabian H. Leendertz and Roman M. Wittig joint senior author

This is an open access article under the terms of the [Creative Commons Attribution-NonCommercial-NoDerivs](https://creativecommons.org/licenses/by-nc-nd/4.0/) License, which permits use and distribution in any medium, provided the original work is properly cited, the use is non-commercial and no modifications or adaptations are made.

© 2023 The Authors. *Methods in Ecology and Evolution* published by John Wiley & Sons Ltd on behalf of British Ecological Society.

and a particular focus on wild chimpanzees. Methods in acquiring brain tissue from wild settings are comprehensively explained, highlighting the feasibility of conducting brain extraction procedures under strict biosafety measures by trained veterinarians in field sites.

3. Brains are assessed at a fine-structural level via high-resolution MRI and state-of-the-art histology. Analyses confirm that excellent tissue quality of primate brains sourced in the field can be achieved with a comparable tissue quality of brains acquired from zoo-living primates.
4. Our field methods are noninvasive, here defined as not harming living animals, and may be applied to other mammal systems than primates. In sum, the field protocol and methodological pipeline validated here pose a major advance for assessing the influence of socio-ecology on medium to large mammal brains, at both macro- and microstructural levels as well as aiding with the functional annotation of brain regions and neuronal pathways via specific behaviour assessments.

KEYWORDS

brain connectivity, brain evolution, brain extraction, brain microstructure, field necropsy, MRI, socio-ecological factors

1 | INTRODUCTION

Both dramatic increases in brain size relative to body size and brain reorganisation processes are apparent across evolution throughout mammal, and especially primate, lineages (Barton, 2012; Bryant & Preuss, 2018; Jerison, 1970; Sol et al., 2008). Examples include the emergence of a third temporal gyrus exclusively in hominoid lineages (Bryant & Preuss, 2018) and the extension of the dorsal white matter tract deep into the temporal lobe, considered critical for language and exclusively being evident in humans (Rilling et al., 2008). Brain region variation can co-occur with socio-ecological variation, such as group size, dominance, predation, or pregnancy (Hoekzema et al., 2017; Reddon et al., 2018; Sallet et al., 2011), with early-life experience also considered to be influential (Bogart et al., 2014; Buss et al., 2012; Miguel et al., 2019). Moreover, frequently performed behaviours may alter related brain structures suggesting considerable plasticity (e.g. Maguire et al., 2000; Pope et al., 2018; Quallo et al., 2009). Individual differences emphasise the need for a representative sample of brains from individuals that have lived in highly variable socio-ecological environments, including the natural habitat. To acquire datasets with both suitable brain and behaviour measures, interdisciplinary approaches involving neuroscientists, evolutionary biologists, and ethologists are required.

Analysing the brains of living animals has been conducted via capturing electrophysiological signals of brains, or neuroimaging of anaesthetised captive animals (Martin, 2014). Another invasive approach depends on obtaining post mortem tissue suitable for macro- or micro-structure analyses by killing study animals (e.g. Atapour et al., 2019; Saraf et al., 2019). Due to ethical issues,

invasive studies are nowadays avoided whenever possible and are off limits for certain species such as the great apes (Padrell et al., 2021). Hence, our knowledge of the brain structure of our closest living relatives is drawn from a brain sample that is difficult to replenish and lacks specimens from wild populations. (e.g. Iwaniuk, 2010; <https://primatebrainbank.org>; Kaas & van Eden, 2011; <http://www.chimpanzeebrain.org>; *National Chimpanzee Brain Resource* (RRID:SCR_019183), n.d.). Furthermore, existing collections are largely comprised of specimens from adult animals; hence little is known about ontogenetic processes.

Primates offer a particularly suitable system to test hypotheses about brain evolution, given their remarkable diversity in social systems and ecology, and variation in relative brain size and reorganisation (Barton, 2012; Bryant & Preuss, 2018; Powell et al., 2017; Shultz & Dunbar, 2007). Another advantage of studying primates is the existence of multiple long-term field sites, not only for several species but for different subpopulations living in different habitats. Here, site records offer detailed information about lifetime demography, reproductive and social history. Thus, we can collect data from individuals varying in their habitats, social structures, social networks and strategies, or extractive foraging (including tool use).

Modern high-resolution imaging can showcase brain structures and pathways in unprecedented detail, particularly in brains sourced after (natural) death (Eichner et al., 2020; Friedrich et al., 2021), due to the possibility of using long scanning times. This approach allows for overcoming ethical restrictions when studying the brains of wild and/or endangered animals (almost 60 % of all primate species are threatened with extinction, Estrada et al., 2017; IUCN, n.d.; Junker et al., 2020). Several field sites engage in daily follows of

habituated animals, and occasionally deaths are observed (Wittig & Boesch, 2019), providing the opportunity to obtain tissue for scientific investigation. This study aimed to (1) establish a protocol that allows for safely removing complete primate brains even in remote field sites and (2) to evaluate whether the specimens' quality is adequate for fine structural tissue assessment by state-of-the-art magnetic resonance imaging (MRI) and histological techniques. Tissue quality is additionally assessed in comparison to brains sourced from deceased zoo-housed animals in specialised European pathology institutions.

2 | MATERIAL AND METHODS

2.1 | Pipeline

2.1.1 | Network and training

To obtain a sample of brains from nonhuman primates that have lived under diverse socio-ecological conditions, we work with a growing network of collaborators from sites across Africa, Europe, and Central America (Figure 1). Partnering institutions consist of zoological gardens ($N = 14$), primate sanctuaries ($N = 3$), field sites ($N = 8$) and veterinary pathology laboratories.

The diversity of network partners results in varying conditions under which brain specimens are collected. Regarding European zoos, the bodies of deceased apes are most frequently transported to specialised veterinary pathology units, where experienced teams conduct necropsies. In African sanctuaries, gross pathology is usually performed on-site in a designated room by the veterinary unit. In field sites, necropsies are conducted by the field veterinarian at the location of the primate's death, sometimes many kilometres away from the nearest camp, deep in the rainforest. Where access to specialised pathology services is limited, on-site and local veterinary services are supported with equipment, know-how and staff

to ensure samples can be obtained safely and with the quality required for subsequent analyses. We established a training program conveying the brain removal techniques and biosafety aspects of performing a necropsy. To optimally prepare new veterinarians, supervised necropsy simulations are conducted, meticulously following the various implemented hygiene protocols. Initial brain removal training aims to familiarise with handling the oscillating saw, and cutting coconuts has proven to be a suitable introduction (supplementary material S5). This is followed by extracting the brains of wild or domestic animals at partnering veterinary pathology laboratories. Additionally, the training includes attending a human autopsy due to the anatomical similarity to apes and the associated analogous extraction protocol applied in the field. Our research is conducted according to standards specified by the Max Planck Society's Ethics Committee (04.08.2014).

2.1.2 | Socio-ecological data acquisition from wild and human-managed primates

To maximise socio-ecological diversity between individuals, targeting habituated wild primates from established field sites and those living in zoos or sanctuaries has two benefits. First, this approach offers highly diverse socio-ecologies. Second socio-ecological variables known or hypothesised to impact brain structure are often documented in the site records and hence can be readily accessed after an individual's death. Data collection of particular behaviours of interest related to brain structure, such as communication abilities (Girard-Buttoz et al., 2022), handedness (Margiotoudi et al., 2019), or specific cognitive abilities tested in experiments (e.g. Kopp et al., 2021) can be planned explicitly by individual projects across sites. Death events are stochastic, so predicting final sample sizes for studies relying on brain and behavioural data from the same individuals remains challenging. (For examples of the extent of variation for ecological, social and individual characteristics, see Table 1).

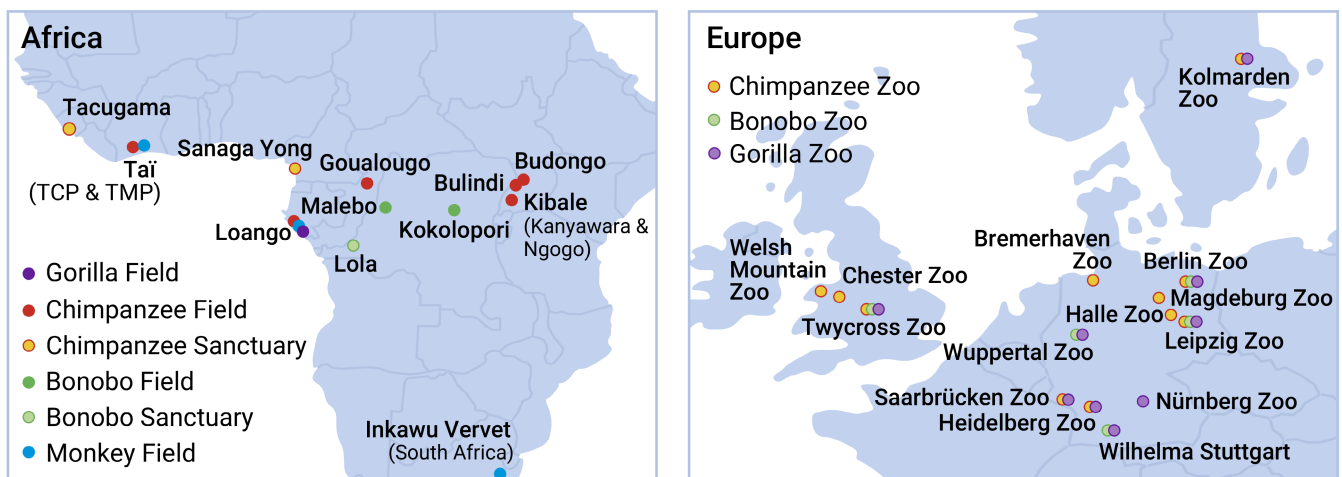

FIGURE 1 Network of collaborating African field sites (including sites for three of the four chimpanzee subspecies) and sanctuaries, and European zoos. Additionally, we collaborate with the capuchins at Taboga Project, Costa Rica.

TABLE 1 Examples in the current sample of individual variation in socio-ecological variables of relevance to brain variation.

Socio-ecological variables of interest	Variation in sample	Articles documenting relevance to brain variation in any species
Individual characteristics		
Subspecies	<i>P. t. verus</i> , <i>P. t. schweinfurthii</i> , <i>P. t. troglodytes</i>	
Sex	M/F	Vijayakumar et al. (2018)
Age	0–56 years	Miller et al. (2012), Mulholland et al. (2021), Sakai et al. (2013) and Skeide and Friederici (2016)
Reproductive history	Pregnant, lactating, cycling, contraception	Hoekzema et al. (2017)
Mothering (years of mothering received)	1–32 years	Schubert et al. (2009), Bennett et al. (2021) and Bogart et al. (2014)
Characteristics of the individual's social group		
Social group size at death	2–150	Meguerditchian et al. (2021) and Sallet et al. (2011)
Lifetime social group size	2–150	Meguerditchian et al. (2021) and Sallet et al. (2011)
Intergroup competition exposure	0–5 neighbouring groups	Connor (2007) and González-Forero and Gardner (2018)
Intrasexual competition exposure (>12 y)	0–31 reproductive competitors (same sex)	Lindenfors et al. (2007)
Intrasexual competition exposure (>12 y)	0–21 reproductive partners (opposite sex)	Lindenfors et al. (2007)
Site ecology variables		
Provisioning	Yes/no	DeCasien et al. (2017)
Predation exposure	Present/absent	Reddon et al. (2018)
Population density	1–100 chimps/km ²	González-Forero and Gardner (2018) and Triki et al. (2019)
Home range/enclosure size	0.1–29 km ²	Harvey et al. (1980) and Powell et al. (2017)
Number of tools used	0–32	Quallo et al. (2009), Reader and Laland (2002) and Whiten et al. (1999)
Novel behaviour observed/reported	Yes/no	Reader and Laland (2002), Sol et al. (2008) and Bandini and Harrison (2020)

2.1.3 | Health monitoring in field sites

High quality, in toto extracted brain specimens constitute the foundation for the Evolution of Brain Connectivity (EBC) project's scientific investigations. Tissue degrades progressively after death, and the causative lytic processes are accelerated at higher temperatures found in sub-Saharan African field sites and sanctuaries (Tsokos & Byard, 2012). Thus, a brief post mortem interval (PMI) before fixation, ideally below 12 h and not exceeding 48 h, is the critical factor for achieving tissue quality suitable for high-resolution MRI scanning and histology. If the PMI is not known from direct observation (habituated primates), an estimate is inferred from the animal remains, considering factors like rigor mortis, algor mortis, fly-larvae infestation and tissue decomposition (Kori, 2018; Lothe, 1964).

Linked to the implemented passive/noninvasive approach, sampling cannot be scheduled, requiring short-term responsiveness in case of an ape fatality. Therefore, a trained veterinarian responsible for the autopsy is permanently based at remote field sites. Trained field assistants routinely assess the individuals' health during daily chimpanzee follows. Health incidents are reported promptly to the veterinarian, who further evaluates the situation and decides

on the next steps. Such incidents largely consist of traumatic injuries inflicted by intra/intergroup aggression or leopard predation (Boesch, 1991; Wilson et al., 2014). Further, important health observations encompass clinical signs indicative of infectious diseases. Depending on the pathogen, infections may be accompanied by a disturbed general condition, lethargy, diarrhoea, coughing, sneezing and/or skin efflorescences (Mubemba et al., 2020). Sick or injured wild chimpanzees may separate from the main group, requiring individual nest-to-nest follows from dawn to dusk. This extensive monitoring might sometimes be necessary for several days or weeks.

2.1.4 | On-site brain removal following biosafety protocols

Despite the importance of rapid brain removal, speed must not compromise biosafety. Primates', and especially apes', close phylogenetic relationship to humans does not only allow for unique insights into hominid brain evolution but further leaves them susceptible to the same pathogens (Calvignac-Spencer et al., 2012). Primates might have succumbed to a deadly disease and spillover during necropsy

could pose a serious risk. This is particularly the case for severe zoonoses like anthrax, Ebola, and monkeypox known to cause wild chimpanzee fatalities (Formenty et al., 1999; Leendertz et al., 2004; Patrono et al., 2020). Thus, post mortem examinations are conducted following a strict hygiene protocol by personnel who have received specific biosafety training. Primates exhibiting signs of severe infection, such as blood leaking out the body orifices or extensive haemorrhages within the body cavities, are excluded from brain extraction and sampled minimally (e.g. swabs of the leaked hemorrhagic fluids). Additionally, an Ebola quick test (OraQuick® Ebola Rapid Antigen Test) can be performed upon initial carcass examination.

To prevent the spread of potential pathogens, autopsies of wild primates are conducted at the location of the animal's death,

sometimes deep in the rainforest. A 10 m radius around the body is designated as the “contaminated zone”. This area is exclusively entered wearing personal protective equipment (PPE), including rubber boots, a coverall, an FFP3 face mask, sleeves, three pairs of gloves and goggles and/or a face shield (Figure 2a). The required necropsy equipment and a step-by-step guide of the PPE dressing and undressing protocol are included in the supporting information (supplementary material S1 and S2). A hygiene barrier is installed, enabling exit of the contaminated zone without pathogen carryover. Here, single-use necropsy material and PPE are discarded in at least two layers of large, durable plastic bags, which are subsequently incinerated in a designated ditch, whereas reusable material and sample containers are decontaminated. Household bleach is implemented as a disinfectant at



FIGURE 2 (a) Necropsy simulation wearing personal protective equipment. Here, the necropsy equipment is prepared and the hygiene barrier is installed. (b) Infant wild chimpanzee positioned for the necropsy and brain extraction. (c) Fully detached skullcap encompassing the brain of an adult chimpanzee. In the background, the inner skull base and the reflected scalp can be seen. (d) Brain suspended in 10 % neutral buffered formalin and hung by a string threaded underneath the basilar artery. (e) Padding of the brain in a leak-proof metal flask for shipping.

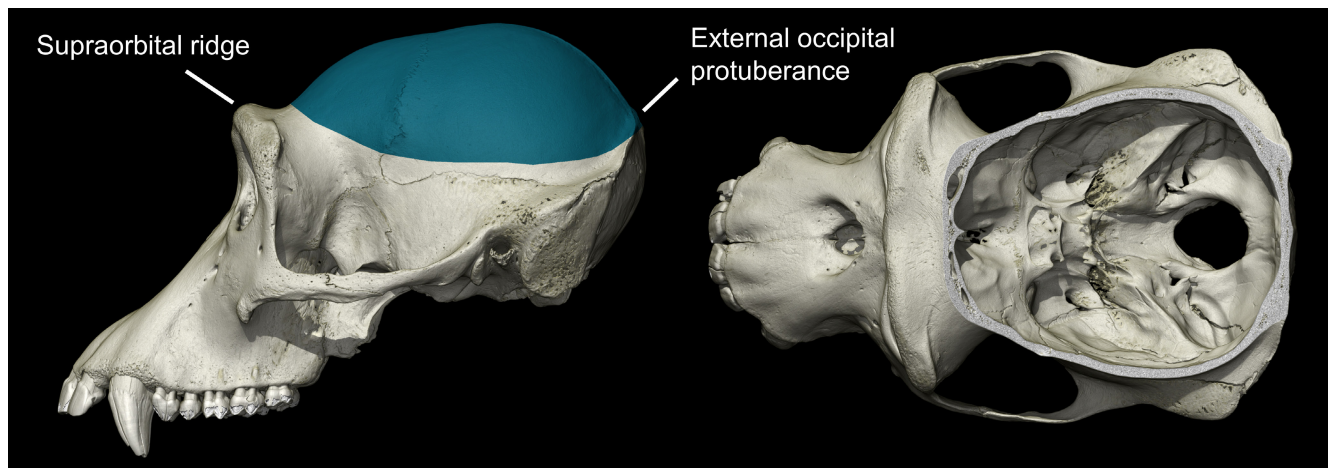


FIGURE 3 Visualisation of the cutline using a micro computed tomography (Micro CT) scan of an adult chimpanzee, in lateral (left) and superior view (right).

a 1 % dilution of its active ingredient sodium hypochlorite. This yields an effective viricidal, bactericidal and sporicidal solution that is readily available even in remote regions (Kenar et al., 2007).

For the necropsy, tarpaulins are used as working surfaces and the body is positioned in dorsal recumbency. To access the head's entire perimeter for the brain extraction, it needs to be elevated and tilted anteriorly by supporting the neck, for example with the help of a log (Figure 2b). The skin is incised from one to the other ear base utilising a scalpel and the resulting scalp parts are undermined and reflected to the front and the back. Subsequently, the temporalis muscles and any remaining soft tissue in the area of the cutline are dissected. The skull is opened extremely cautiously in a circular manner using a battery-operated oscillating saw (KUGEL medical). Landmarks for the sawing path are: (1) Rostral, behind the supraorbital ridge, where the frontal bone starts to slope upwards; (2) caudal, just below the external occipital protuberance (Figure 3). Ideally, the bone is not penetrated in its full width, which would increase the likelihood of damaging the brain. The remaining thin bony ridges are easily cracked by inserting and twisting a t-shaped chisel in the saw line. Subsequently, the exposed dura mater is incised. As the brain is dorsally attached to the skullcap by the falx cerebri, a gentle steady pull on the skullcap can be applied to help visualise and sever basal structures including cranial nerves and blood vessels. A crucial point to recover the complete organ poses the bilateral incision of the tentorium cerebelli, which separates the cerebrum from the cerebellum. At last, the medulla oblongata is cut as caudally as possible and after carefully mobilising the cerebellum, the skullcap, encompassing the brain, can be completely detached (Figure 2c). A string is threaded underneath the basilar artery and the brain is transferred cautiously into 10 % neutral buffered formalin (NBF). The organ is submerged hanging upside down by the string to obviate potential deformation of the tissue (Figure 3d).

In addition to the brain extraction, a complete necropsy of the deceased primate including the collection of an extensive tissue set is performed (supplementary material S3). These samples are used to investigate the cause of death by means of molecular biological,

microbiological, or histological techniques at partnering laboratories (e.g. Leendertz Lab and the German Primate Centre). Depending on the underlying pathogenesis, this might yield important metadata about the brain's tissue quality as assessed via MRI and histology—for example, if a bacterial-induced sepsis caused premature onset of heterolysis (Zhou & Byard, 2011).

2.1.5 | Brain fixation and storage

Concentrated formaldehyde solutions are purchased from local pharmacies and are diluted with phosphate buffered saline (PBS) at a pH of 7.4, which can be prepared on-site using tablets (ROTI®Fair PBS 7.4). For the initial 2 weeks, the tissue is preferably fixed at a cool temperature (4°C–10°C) in 10 % neutral buffered formalin (NBF), followed by storage at ambient temperature. 10 % NBF is renewed following fixed intervals (supplementary material S4). After a total of 3 months, the fixative is reduced to a 2.5 % NBF solution to preclude over-fixation, which would result in a decrease of water diffusion through the tissue, diminishing the quality of diffusion weighted imaging-based tractography. Upon arrival in Leipzig, brains are transferred for long-term storage into a PBS pH 7.4 solution with 0.1 % sodium azide to prevent fungal and bacterial growth and are kept at 4°C.

2.1.6 | Skulls

To relate the variation in brain shape and structure to the endocranial imprint, we also study the cranial bones using micro computed tomography (Micro CT). Skulls, along with the entire body, are defleshed via burying them at the necropsy site for at least six months, at a sufficient depth to avoid excavation by scavengers (at least 1 m). Burial sites are documented using global positioning system (GPS) coordinates and are additionally marked (e.g. by signal tape). The bones are excavated in PPE and disinfected with a 10 % formalin solution. Alternatively,

heads of young individuals may be completely immersed in formalin to prevent disintegration of the not yet fused cranial plates.

2.1.7 | Export and permits

Brain export to Germany is carried out in agreement with the Convention on International Trade in Endangered Species of Wild Fauna and Flora (CITES) and varying national legislation. Within this context our local partners are crucial to liaise with local authorities and to obtain the required permits within the respective countries. An overview of permit issuing authorities and permit numbers is given in supplementary material S6. The brains are shipped in leak-proof metal flasks, after a minimal fixation period of four weeks to warrant sufficient tissue durability. These containers are padded on the inside with trimmed pieces of sponges and filled with 2.5 % NBF (Figure 2e).

2.2 | Tissue quality assessment

2.2.1 | Magnetic resonance imaging (MRI)

We qualitatively evaluated the image quality, contrast and level of artefacts for high-end MRI protocols including: (1) MRI microscopy to characterise brain anatomy with the highest possible resolution; (2) ultra-high-resolution quantitative MRI to study the microstructure of brain tissue; (3) diffusion MRI to study brain microstructure and connectivity. For MRI acquisition the brains were placed in an egg-shaped (7 T structural MRI) or spherical (9.4 T diffusion MRI) acrylic container. They were embedded in a proton-free MRI-invisible liquid (Fomblin®, Solvay) and degassed in vacuum for several hours to remove air bubbles.

MRI microscopy and quantitative MRI

Structural MRI was performed on a human 7 T Terra MRI scanner (Siemens Healthineers, Erlangen, Germany), using a 32-channel human receive head coil (Nova Medical, Wilmington, MA). MRI microscopy images, weighted by the effective transverse relaxation $T2^*$ ($T2^*WI$), were acquired using a fast low-angle shot magnetic resonance (FLASH) sequence at an isotropic resolution of $200\mu\text{m}$ (repetition time (TR) = 70 ms; echo time (TE) = 15 ms, flip angle 31°) with a total acquisition time of 2 h. Quantitative maps of MR parameters were obtained via a multi-parametric mapping method (MPMs; Weiskopf et al., 2015, 2021) using multi-echo 3D FLASH acquisitions with isotropic resolutions of $300\mu\text{m}$. Three acquisitions weighted by proton density (PD, flip angle 18°), longitudinal relaxation time $T1$ (flip angle 84°) and by magnetisation transfer (MT saturation pulse: Gaussian at 3 kHz offset, flip angle 700°) were acquired, together with calibration scans for the transmit field $B1^+$ (Lutti et al., 2010, 2012). Quantitative maps of MRI parameters were reconstructed with the help of an optimised pipeline in the hMRI toolbox optimised for 7 T post mortem imaging (www.hMRI.info, Tabelow et al., 2019).

To correct the bias in the MTsat maps induced by inhomogeneity of the transmit radio-frequency field we developed the calibration approach described in detail in (Lipp et al., 2022).

Diffusion MRI (dMRI)

Whole-brain dMRI data were acquired on a preclinical Bruker Biospec 94/30 MRI system at 9.4 T (Paravision 6.0.1), using a 300mT/m gradient system and a 154mm transmit-receive quadrature RF coil (Bruker BioSpin). Data were acquired with an isotropic resolution of $500\mu\text{m}$, using a segmented 3D EPI spin-echo sequence (matrix-size: $240 \times 192 \times 144$; TR = 1000 ms; TE = 58.9 ms, no Partial Fourier, no parallel acceleration, EPI segmentation factor = 32). Diffusion-weighting was applied with $b = 5000\text{s/mm}^2$ in 58 directions, distributed across a full sphere. Three interspersed $b = 0$ images were acquired for motion and field drift correction. An additional $b = 0$ image with reversed phase encoding was acquired for distortion correction (Andersson et al., 2003). A noise map with matching imaging parameters was recorded for noise debiasing (Gudbjartsson & Patz, 1995). The total dMRI acquisition time for each brain was approximately 90 h.

Diffusion MRI preprocessing included (1) signal debiasing (Gudbjartsson & Patz, 1995), (2) MP-PCA denoising (Veraart et al., 2016), (3) 3D volumetric Gibbs ringing correction using sub-voxel shift (Kellner et al., 2016), (4) field-drift correction (Vos et al., 2017), (5) distortion correction (Andersson & Sotiropoulos, 2016). Next, (6) a diffusion tensor imaging (DTI) model was fit to the dMRI volume to reconstruct local white matter anisotropy, generating maps of DTI fractional anisotropy (FA), DTI mean diffusivity (MD), and DTI fibre direction.

2.2.2 | Histology

State-of-the-art histology was applied to a subset of nine brains. Brains were cut in 15mm thick coronal slabs and cryoprotected in 30 % sucrose in PBS pH 7.4 with 0.1 % sodium azide. $30\mu\text{m}$ sections were cut on a cryomicrotome (Thermo Scientific, Microm HM430, freezing unit Thermo Scientific, Microm KS34). Sections were collected in PBS pH 7.4 with 0.1 % sodium azide and stored in sealed sample glasses at 4°C until further use. To facilitate co-registration between MRI and histology, block-face imaging was applied during sectioning (Alkemade et al., 2020; Brammerloh et al., 2021). Consecutive sections were stained with histological and immunohistochemical methods.

To investigate cortical cytoarchitecture and tissue integrity, Nissl staining with acetate-buffered cresyl violet was applied. Silver-based visualisation of myelin was carried out by a modified Gallyas stain. Immunohistochemical stains were applied to reveal preservation of protein/epitope content with several antibodies (neurons: mouse-anti-HuC/D, Invitrogen A21271, concentration 1:4000; myelin: rat-anti-MBP, abcam ab7349, concentration 1:1000; astrocytes: rabbit-anti-GFAP, DAKO Z0334, concentration 1:5000; microglia: rabbit-anti-IBA1, concentration 1:2000, Fujifilm Wako Pure Chemical Corporation 019-19741).

3 | RESULTS

3.1 | Brain collection

Overall 28 chimpanzee brains (11 females, mean age = 23 ± 19 y) were collected during the period from June 2018 to October 2021 (Table 2). Fourteen brains (five females, mean age = 18 ± 17 y), including three of the four subspecies, were collected at field sites in Ivory Coast, Uganda and Gabon. Fourteen brains (six females, mean age = 28 ± 19 y) originated from a sanctuary in Sierra Leone and zoos in Germany, UK and Sweden (six and eight brains, respectively). Subspecies included *P. t. verus* ($N = 15$), *P. t. schweinfurthii* ($N = 4$), *P. t. troglodytes* ($N = 3$) and currently unknown ($N = 6$). Note that brains collected in zoos were mainly from older adults (six cases >40 years). In comparison, the majority of brains collected in the African field sites and sanctuaries belonged to infants or juveniles (eight cases <10 years), and subadults or young adults (eight cases: 10–18 years). Note that some chimpanzees' ages had to be estimated.

While the current focus of the brain bank is on chimpanzees, together with our network partners, we have also collected brains of other great apes and several monkey species both in field sites and zoos, demonstrating that this tissue collection approach is generally applicable to primates (Table 3).

3.2 | Causes of death

The causes of death for chimpanzees from field sites included bacterial infections ($N = 4$), conspecific aggression ($N = 4$), human-animal conflict ($N = 2$), leopard attack ($N = 2$), emaciation due to chronic renal disease ($N = 1$) and emaciation due to maternal loss ($N = 1$).

The cause of death for chimpanzees that died at sanctuaries and zoos were cardiovascular diseases ($N = 5$), brain and abdominal tumours ($N = 3$), conspecific aggression ($N = 2$), renal disease ($N = 1$), epileptic episode ($N = 1$) and unknown causes ($N = 2$).

3.3 | Brain integrity

Three brains collected at field sites were partially damaged by conspecific or human aggression. For four brains, collected at sanctuaries and zoos, brain parts were missing due to extraction artefacts, tumour, or head injury prior to death. Small blocks (about 1 cm^3) were missing for some brains as a result of extraction artefacts or due to tissue dissected for diagnostic histology, with the same frequency for field sites, zoos and sanctuaries. Minor superficial cuts, caused by sawing (up to 5 mm deep) and damages on the brain stem inflicted during brain extraction, were apparent for some brains from field sites, sanctuaries, and zoos. Some superficial damage occurred during the transport of three brains collected at field sites and one brain collected from a zoo animal. This type of damage occurred in

the project's first year and was subsequently mitigated by improved packing and transport procedures (Figure 4).

3.4 | Tissue fixation

Mean post mortem interval before fixation (PMI) was 12 ± 8 h for brains collected at field sites and was only 3 h longer than the mean PMI = 9 ± 7 h for brains collected at sanctuaries and zoos (see Table 2).

Lytic tissue damages were observed in MRI scans of three brains collected at field sites, manifested as liquid-filled cavities in the white matter. Brains exhibiting signs of tissue lysis had a prolonged PMI of ≥ 24 h (though in one case 12 h); and two of them were collected from animals who had died due to bacterial infections.

Homogeneous tissue fixation was achieved for nine of 14 brains collected at field sites (90 % of all brains, excluding brains from individuals with systemic bacterial infections) and 12 of 14 brains collected at sanctuaries and zoos (85 %; Tables 2 and 3; Figure 5).

Heterogeneous tissue fixation with the gradient from brain surface to the brain centre, most likely corresponding to the front of fixative diffusing into the tissue, was visible in T1w-MRI images of two brains collected at field sites and two brains collected at sanctuaries and zoos.

3.5 | Magnetic resonance imaging

All brains from individuals with pronounced cortical myelination (>1.5 years) exhibited high contrast between grey and white matter in MRI with PD, T2*, T1 and MT weightings. Particularly the maps of magnetisation transfer saturation (MTsat) showed high homogeneity, low levels of fixation artefacts, and high white-grey matter contrast (Figure 5). MTsat maps were identified as the most suitable input for automated brain segmentation algorithms. T1w images, commonly used as input for segmentation algorithms in human in vivo studies, also showed grey-white matter contrast, but were affected by tissue fixation gradients in brains with long PMI and brains of individuals with systemic bacterial infections. The grey-white matter contrast in MTsat images was comparable between brains collected in field sites and brains originating from zoos and sanctuaries (Figure 5). Thus, comparable brain segmentation can be achieved on brains collected at field sites, sanctuaries and zoos.

MRI microscopy of brains collected in the field, sanctuaries and zoos demonstrated preserved brain anatomy of macroscopic and mesoscopic brain structures (Figure 6). This is verified by clearly visible MRI contrast in mesoscopic anatomical structures, including cortical layers in the neocortex (Figure 6Ai,Bi), subfields in the hippocampus (Figure 6Aii,Bii) and nuclei in the subcortex (Figure 6Aiii,Biii). High and comparable qualities of ultra-high-resolution T2* weighted images were achieved in brains collected in the field, sanctuaries and zoos, enabling studies on small anatomical features.

TABLE 2 Chimpanzee brains collected at field sites (a) and at zoos or sanctuaries (b) between 2018 and 2021. PMI—post mortem interval, BS—brainstem, WM—white matter, RH—right hemisphere, TH—thalamus; FL—frontal lobe, TL—temporal lobe, PL—pallidum. Yellow: Infants and juveniles. Blue: Subadults and adults. Grey: Older individuals (>40 years). Cuts of less than 15 mm depth are referred to as superficial, cuts with the depth larger than 15 mm are referred as deep. N.y.a.: Not yet assessed. N.d.y.: None detected yet.

Age, year	Sex	PMI, h	Tissue quality (MRI)	Brain integrity	Pathology ^a	Suitable for comparative neocortical anatomical MRI analysis	Suitable for comparative connectivity analysis (dMRI)	Suitable for comparative histology
(a) Field sites								
0,1	M	4	Good	Damaged RH	Traumatic injury RH	Yes	Yes	Yes
1	M	4,5	Good	FP missing	N.d.y.	Yes	Yes	N.y.a.
1,75	M	24	Autolysis in WM and TH, cortex good	Slight surface damages, missing parts, ca. 1 cm ³	Bacterial infection	Yes	No	Yes
2,6	M	3,5	Good	Intact	N.d.y.	Yes	Yes	N.y.a.
6	F	5	Good	Superficial cuts, missing parts, ca. 1 × 1 × 2 cm	Inflammation, astrogliosis	Yes	Yes	Yes
13	F	15	Autolysis in WM in TL, cortex good	Slight surface damages	N.d.y.	Yes	Yes	N.y.a.
14	F	24	Autolysis in WM and TH, fixative gradient in the cortex	Superficial cuts, brainstem separated, missing parts ca. 2 × 2 × 2 cm	Bacterial infection	No	No	Yes
15	M	12	Fixative gradient in the cortex	Deep cuts	Bacterial infection	No	Yes	Yes
16	M	11	Good	Deep cut on brainstem	Bacterial infection	No	No	Yes
18	M	11	Autolysis in WM, fixative gradient in the cortex	Intact	N.d.y.	Yes	N.y.a.	N.y.a.
30	M	12	Good	Damaged RH	Traumatic injury RH	Yes	Yes	Yes
40	F	25	Good	Intact	N.d.y.	Yes	Yes	N.y.a.
45	M	14,5	Good	Intact	N.d.y.	Yes	N.y.a.	N.y.a.
56	F	2,6	Good	Intact	N.d.y.	Yes	N.y.a.	N.y.a.
(b) Sanctuaries and zoos								
-0,2	M	12	Good	Intact	N.d.y.	Yes	N.y.a.	N.y.a.
1,55	M	17	Good	Intact	N.d.y.	Yes	Yes	N.y.a.
6,5	F	5	Good	Intact	N.d.y.	Yes	N.y.a.	N.y.a.
10	M	5	Good	Superficial cuts, FL missing, BS missing	N.d.y.	Yes	N.y.a.	N.y.a.
12	F	2	Good	Deep cuts for diagnostics	Brain tumour	No	No	Yes
12	M	6	Good	Superficial cuts, cerebellum and part of BS missing	Occluded vessels in PL	Yes	N.y.a.	Yes
34	M	5	Good	Superficial cuts, missing parts, ca. 1 × 1 × 1 cm ³	Cortical microbleeds	No	Yes	Yes
36	M	20	Good	Intact	N.d.y.	Yes	N.y.a.	N.y.a.

(Continues)

TABLE 2 (Continued)

Age, year	Sex	PMI, h	Tissue quality (MRI)	Brain integrity	Pathology ^a	Suitable for comparative neocortical anatomical MRI analysis	Suitable for comparative connectivity analysis (dMRI)	Suitable for histology
43	F	1	Good	Superficial and deep cuts in TH and BS	N.d.y.	Yes	Yes	N.y.a.
44	F	1	Good	Superficial cuts, deep cuts in PL	PL calcifications, enlarged Virchow spaces	Yes	Yes	Yes
45	M	12	Good	Superficial cut	Cortical microbleeds	Yes	N.y.a.	N.y.a.
47	F	4	Good	Superficial cut	N.d.y.	Yes	Yes	Yes
52	M	24	Good	Superficial cuts, surface damage	Enlarged Virchow spaces, occluded vessels in PL	Yes	Yes	N.y.a.
53	F	11	Good	Intact	N.d.y.	Yes	N.y.a.	N.y.a.

^aPathology: Ongoing analysis, findings listed as assessed up until writing this manuscript.

The acquired dMRI data showed high quality, with both a good directional and microstructural white matter contrast. The data quality is noticeable in the colour FA data, which are compared in Figure 7 for two adult chimpanzee brains, one collected at a field site, the other stemming from a zoo. Excellent image contrast is evident in dMRI images of both samples. Visual comparison shows that even under field conditions tissue may be obtained that enables the acquisition of excellent dMRI data, facilitating studies on brain connectivity and microstructure.

3.6 | Histology

Histological screening of a subset of chimpanzee brains revealed overall good tissue property preservation, whether they originated from field sites or not, allowing for a broad range of histological investigations. The established staining techniques for visualising cyto- and myeloarchitecture provided histological data of high quality useful for qualitative and quantitative analyses. Neurons and fibres were well preserved as seen in Nissl and Gallyas stains (Figure 8) enabling studies on cortical cyto- and myeloarchitecture.

The immunohistochemical stains revealed excellently preserved protein epitopes, resulting in good and over the sample range comparable staining of neurons (HuC/D), astrocytes (GFAP), myelin (MBP) and microglia (IBA1). The distinct visualisation of glial antigens unveiled specific information on the tissue inflammation status.

4 | DISCUSSION

Sourcing brains from deceased primates at a quality that allows for high-resolution MRI and state-of-the-art histology generally requires a coordinated team effort and trained personnel to ensure short post mortem times and skillfully extracted brains, regardless of the primate's origin. Thus, it is understandable why most existing brain banks (e.g. Iwaniuk, 2010; <https://primatebrainbank.org>; Kaas & van Eden, 2011; <http://www.chimpanzeebrain.org>; *National Chimpanzee Brain Resource* (RRID:SCR_019183), n.d.) largely consist of brains originating from primates housed under human care. Since animals are closely monitored by zookeepers, a primate fatality is promptly detected. Additionally, dead bodies are usually transported to veterinary pathology laboratories, where samples are obtained by specialised personnel. Conversely, primates in the wild typically die without notice and pathological facilities might be unavailable. Moreover, especially wild primates might have died of a severe zoonotic disease, requiring strict biosafety precautions when handling a carcass (Hoffmann et al., 2017). All these challenges have been successfully managed with the presented approach, resulting in high tissue quality brains sourced from wild primates that are on a par with the sample quality of brains from primates housed under human care. Thus, we offer a diversification of primate brain collections in terms of socio-ecological variability,

TABLE 3 Additional primate brains (excluding chimpanzees) collected at zoos, sanctuaries and field sites between 2018 and 2021. Dash: Missing information.

Age, year	Sex	Species (English)	Species (scientific)	PMI, h
Sanctuaries and zoos				
43	F	Western lowland gorilla	<i>Gorilla gorilla gorilla</i>	4
33	F	Western lowland gorilla	<i>Gorilla gorilla gorilla</i>	27
33	F	Western lowland gorilla	<i>Gorilla gorilla gorilla</i>	>24
8	M	Bonobo	<i>Pan paniscus</i>	—
31	M	Bonobo	<i>Pan paniscus</i>	—
Field sites				
Adult	M	Western red colobus	<i>Piliocolobus badius</i>	<12
Infant	—	Western red colobus	<i>Piliocolobus badius</i>	—
Adult	—	Western red colobus	<i>Piliocolobus badius</i>	—
Adult	M	King colobus	<i>Colobus polykomos</i>	12–24
Infant (0.25)	M	Vervet monkey	<i>Chlorocebus pygerythrus</i>	4
Infant (0.3)	M	Vervet monkey	<i>Chlorocebus pygerythrus</i>	10
Adult	M	Vervet monkey	<i>Chlorocebus pygerythrus</i>	10
Adult	F	Sooty mangabey	<i>Cercocebus atys</i>	7
Infant	F	Sooty mangabey	<i>Cercocebus atys</i>	<14
Adult	M	Sooty mangabey	<i>Cercocebus atys</i>	<24
Adult	—	Diana monkey	<i>Cercopithecus diana</i>	>16
Adult	—	Diana monkey	<i>Cercopithecus diana</i>	<12
Adult	M	Colombian white-faced capuchin	<i>Cebus capucinus</i>	24
Infant	—	Colombian white-faced capuchin	<i>Cebus capucinus</i>	<12

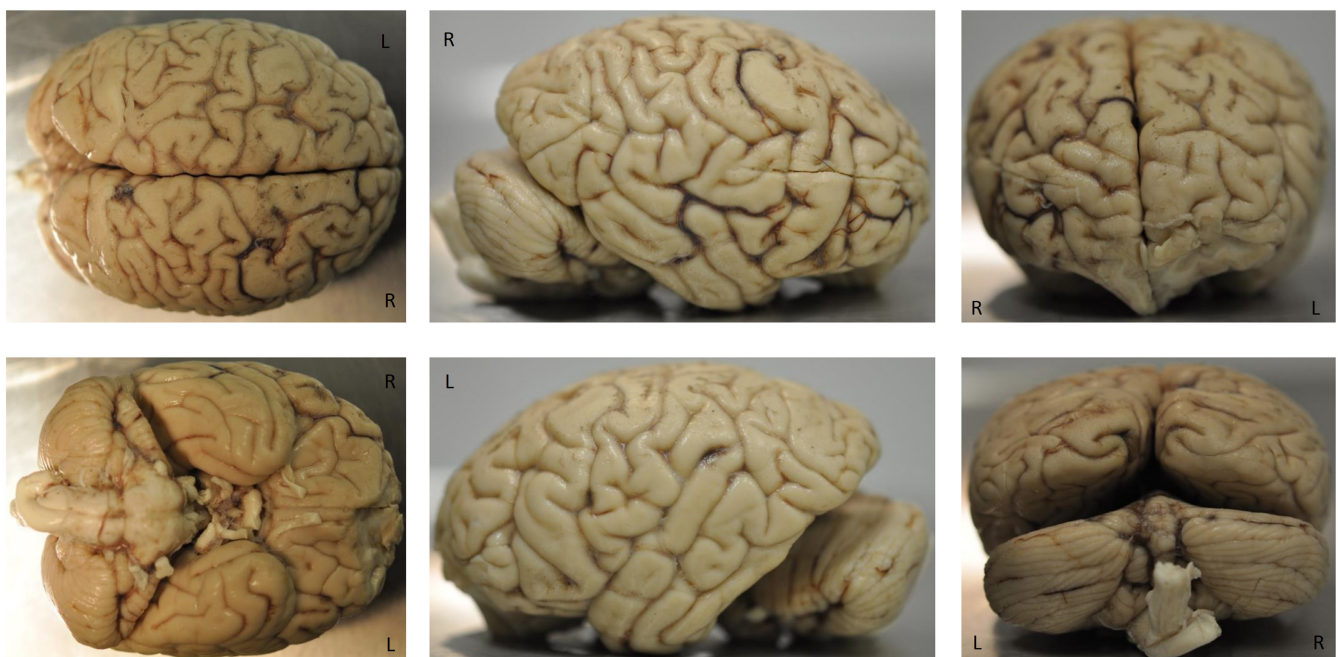


FIGURE 4 Well-preserved chimpanzee brain of a male, 45 year old chimpanzee collected in a field site (Tai Forest, Ivory Coast) less than 24 h post mortem.

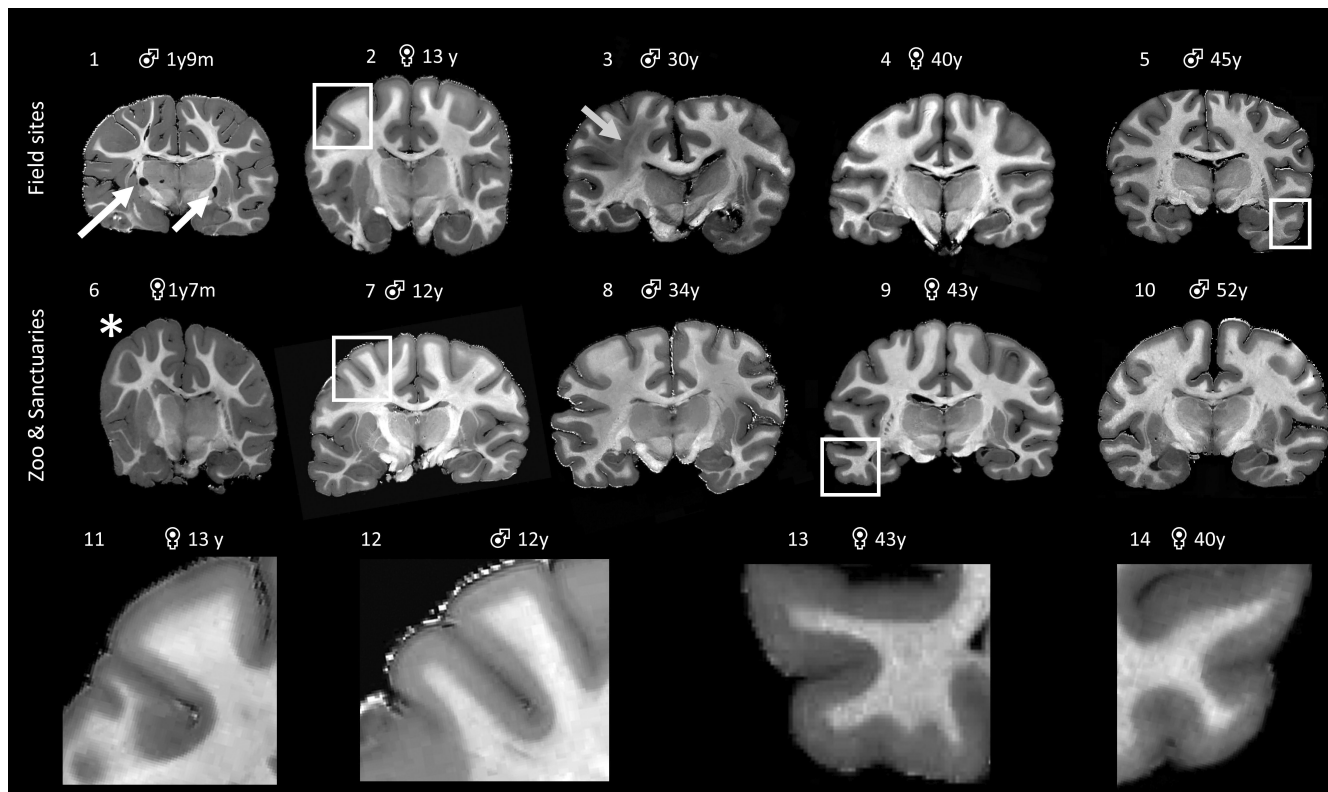


FIGURE 5 Magnetisation transfer saturation (MTsat) whole brain maps of post mortem chimpanzee brains collected at field sites (1–5) and from zoo- or sanctuary-housed animals (6–10). High contrast between grey and white matter (areas within white squares enlarged as 11–14) indicates comparable tissue quality enabling investigations of cortical anatomy, cortical myeloarchitecture, and precise assessment of cortical thickness across development. Artefacts are observed in some brains, both from field sites and zoos/sanctuaries, including liquid-filled cavities in white matter due to tissue lysis (white arrows), brain deformation during fixation (asterisk), or brain damages due to pre mortem injuries (grey arrow).

demographic structure, and ontogenetic profiles. In addition, samples collected during necropsies provide invaluable opportunities to understand pathogens in wild primates, this being of importance for emerging infectious diseases and conservation (Leendertz et al., 2006).

We demonstrated for the first time that high-quality structural MRI and dMRI data could be obtained for brains sourced in the wild. Such data allow us to assess the anatomy and connectivity of these primate brains, which can be compared with *in vivo* MRI and dMRI metrics of other primates, including humans, and therefore enable biologically meaningful evolutionary comparisons across populations and species. For great apes, ethical concerns have prevented new *in vivo* data acquisition for more than a decade. Thus, noninvasive post mortem imaging, as used in this study, is currently the only option to apply recent advances in brain imaging to great ape research. Further, the employed specialised imaging methods, relying on ultra-high field MRI systems, enable much finer brain mapping than what would be achievable with the current *in vivo* techniques due to lack of motion and longer possible scanning times. Particularly the use of quantitative MRI allowed us to minimise instrumental biases in the myelin and iron sensitive MRI maps and ensured maximal compatibility between the brains despite unavoidable differences in fixation

procedure and tissue quality as well as fixation artefacts (Weiskopf et al., 2021).

The histological analysis revealed very good tissue preservation as expressed by maintained cellular structures and several brain-specific epitopes. No substantial differences between brain tissue acquired from field sites, sanctuaries, and zoos could be detected in the histological assessment, and the collected tissue can be compared to state-of-the-art human neuropathology tissue bank collections. Prospectively, the high quality of the collected tissue most likely allows analyses with a vast variety of antibodies, and potentially even the application of different *in situ* techniques (e.g. RNAscope, CISH, FISH) (Grabinski et al., 2015; Liu et al., 2010).

Integral to the success of our pipeline are daily follows of wild habituated primates and a prompt line of communication when a fatality is detected. Strengthening veterinary services in remote sites and thorough training to prepare veterinarians to conduct necropsies and extract minimally damaged brains bio-safely in the middle of the rainforest pose another key factor. This is further reflected in the observation that the quality of tissue samples, regarding brain integrity and tissue fixation, has progressively improved with the refinement of training protocols.

FIGURE 6 MRI microscopy (T2*WI) demonstrates that the high quality of post mortem chimpanzee brain tissue collected in the field site (a) is comparable with the quality of the tissue collected from zoo-living chimpanzees (b). Both brains were extracted less than 24 h after death. Brain integrity is demonstrated by preserved MRI contrast, which allows visualisation of fine anatomical features such as layering in the neocortex (i), anatomy of hippocampal area (ii), and subcortical structures (iii). Cd = caudate nucleus; Pu = putamen; GP = globus pallidus; Th = thalamus; Ver = vermis cerebelli. (i) V1 = visual cortex, Brodmann area 17; V2 = visual cortex, Brodmann area 18; Cb = cerebellum. (ii) S = subiculum; DG = dentate gyrus; Ent = entorhinal cortex. (iii) Th (MD) = mediodorsal thalamic nuclei; Th (VL) = ventrolateral thalamic nuclei; R = red nucleus; STh = subthalamic nucleus; Cp = cerebral peduncle. Nomenclature of anatomical structures: Mai et al. (2004).

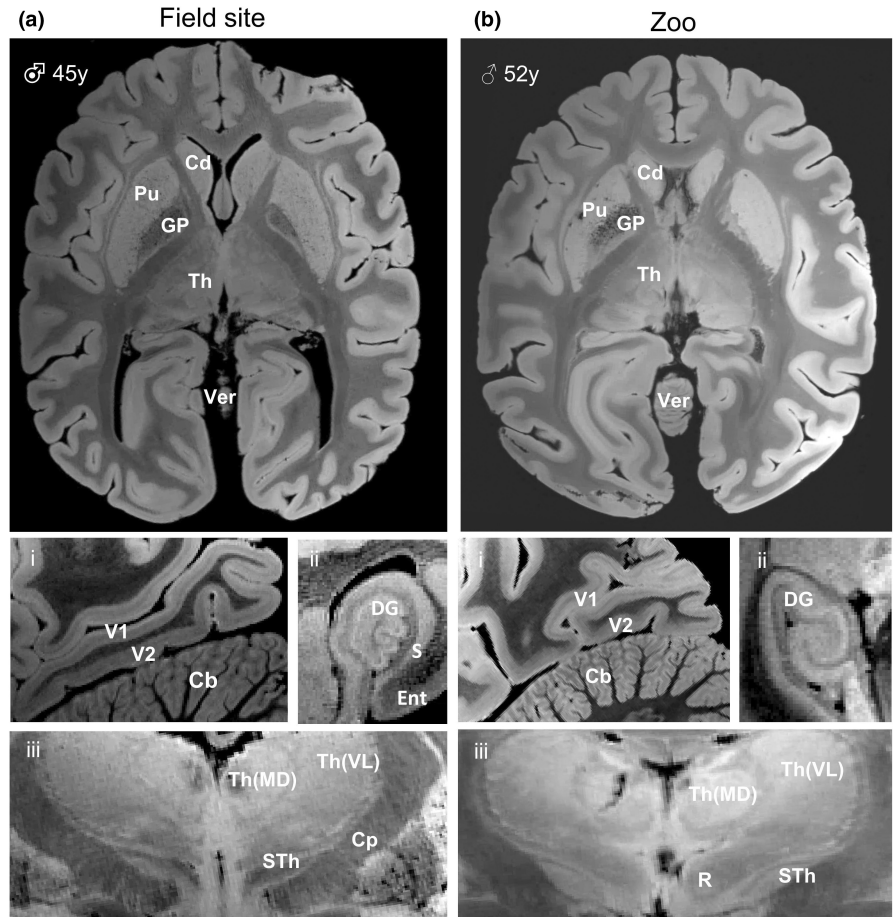
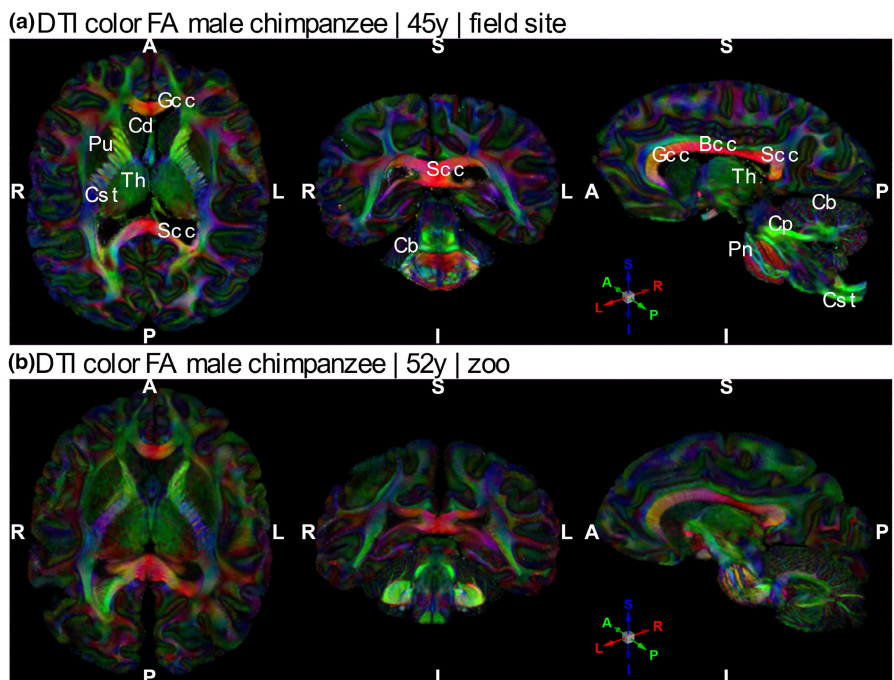


FIGURE 7 Post mortem dMRI demonstrates preserved white matter fibres in chimpanzee brains. DTI colour FA reconstruction of chimpanzee brain that was collected at a field site (upper row, a) and sourced from a zoo (bottom row, b). The colours encode the main fibre orientation in each voxel. Bcc = body of corpus callosum; Cp = cerebellar peduncle; Cst = corticospinal tract; Gcc = genu of corpus callosum; Pn = pons; Scc = selenium of corpus callosum



Due to the work in remote sites, including the considerable effort to ensure biosafety, this approach is limited by its operational expense. Since death events are stochastic, it may be advantageous to gear study design to test more than one hypothesis. The issue

of smaller sample sizes may be resolved over time as collaborative projects acquire reasonable sample sizes.

The Evolution of Brain Connectivity (EBC) project is committed to the conservation and protection of primate species, which




FIGURE 8 Histological validation of tissue quality. Tissue sections of chimpanzee brains collected at field site (top, PMI <16 h, occipital, V1), a sanctuary (middle, PMI 6 h, occipital, V1) and a zoo (bottom, PMI 4–6 h, temporal) were stained with classical histology, histochemical and immunohistochemical methods, revealing high quality in general with excellently preserved epitopes, tissue properties and proteins for neuronal, myelin-associated and glial antigens.

is supported by the presence of researchers in the forests and the recruitment of range country staff. We also train within-country students (e.g. Ivory Coast and Gabon) and veterinarians in countries of primate origins and work in cooperation with local research institutions and field projects for the overall functioning of the EBC Project. The EBC consortium combines researchers from multiple disciplines and many countries.

AUTHOR CONTRIBUTIONS

EBC participants conceived the study. Catherine Crockford, Roman M. Wittig, Tobias Gräßle, Ariane Dux, Fabian H. Leendertz, Carsten Jäger and Markus Morawski devised and established the field methods and brain accessing pipeline; Roman Wittig, Catherine Crockford, Kathrin S. Kopp, Fabian H. Leendertz, Tobias Gräßle and Ariane Dux established the brain network; Philipp Gunz designed the CT based skull analysis methods; Cornelius Eichner, Ilona Lipp, Michael Paquette, Alfred Anwander, Evgeniya Kirilina and Nikolaus Weiskopf developed MRI study design. Ilona Lipp, Evgeniya Kirilina,

Kerrin Pine and Luke Edwards developed anatomical MRI sequences and qMRI analysis methods and performed anatomical MRI measurements and analysis; Cornelius Eichner, Michael Paquette, Angela D. Friederici and Alfred Anwander developed and performed dMRI measurements and analyses; Carsten Jäger, Anna Jauch, Evgeniya Kirilina and Markus Morawski designed the histological pipeline; Carsten Jäger, Anna Jauch and Markus Morawski performed histological experiments and optical imaging and established the brain banking.

ACKNOWLEDGEMENTS

We are grateful for research and brain extraction permissions in Sierra Leone to Environmental Protection Agency; in Côte d'Ivoire to the Ministère de l'Enseignement Supérieur et de la Recherche Scientifique and the Ministère de Eaux et Forêts in Côte d'Ivoire, and the Office Ivoirien des Parcs et Réserves; in Gabon to Ministère des Eaux, des Forêts, de la Mer, de l'Environnement, the Agence Nationale des Parcs Nationaux, the Research Institute for Tropical Ecology,

the National Center for Scientific and Technological Research; in Uganda to the Uganda Wildlife Authority, the Ugandan National Council for Science and Technology, in Costa Rica, the Universidad Técnica Nacional and the Ministerio de Ambiente y Energía. We are grateful to the Centre Suisse de Recherches Scientifiques en Côte d'Ivoire for their logistical support, and the staff members of the Taï Chimpanzee Project for their support and assistance in collecting the data, and to Christophe Boesch for tremendous work in establishing and nurturing the Taï Chimpanzee Project for 30 years. We thank all members of EAZA, PASA and field site partners who have welcomed and worked with us on the Evolution of Brain Connectivity Project. We especially thank Christina Kompo for adeptly handling import and export permits and shipping. This study was funded by the Max Planck Society under the interinstitutional funds of the president for the Evolution of Brain Connectivity Project. Nikolaus Weiskopf has received funding from the European Research Council under the European Union's Seventh Framework Programme (FP7/2007-2013) / ERC grant agreement n° 616905; from the European Union's Horizon 2020 research and innovation programme under the grant agreement No 681094; from the BMBF (01EW1711A & B) in the framework of ERA-NET NEURON. Open Access funding enabled and organized by Projekt DEAL.

CONFLICT OF INTEREST

This work is not subject to any conflict of interest. We note that the Max Planck Institute for Human Cognitive and Brain Sciences has an institutional research agreement with Siemens Healthcare. Nikolaus Weiskopf holds a patent on acquisition of MRI data during spoiler gradients (US 10,401,453 B2). Nikolaus Weiskopf was a speaker at an event organised by Siemens Healthcare and was reimbursed for the travel expenses.

PEER REVIEW

The peer review history for this article is available at <https://publons.com/publon/10.1111/2041-210X.14039>.

DATA AVAILABILITY STATEMENT

Data relevant to this publication is included in the manuscript.

ETHICAL CONSIDERATIONS

While comparative *in vivo* methods have produced some insight into brain function across phylogeny, these methods are compromised by ethical concerns. Our post mortem brain extraction methods are noninvasive in the sense that they do not harm the living animal.

EBC CONSORTIUM


Karoline Albig¹⁴, Bala Amarasekaran¹⁵, Sam Angedakin^{16,17}, Alfred Anwander⁶, Daniel Aschoff¹⁸, Caroline Asimwe¹⁹, Laurent Bailanda²⁰, Jacinta C. Beehner^{21,22}, Raphael Belais²³, Thore J. Bergman^{21,22}, Birgit Blazey²⁴, Andreas Bernhard²⁵, Christian Bock²⁶, Pénélope Carlier⁵, Julian Chantrey²⁷, Catherine Crockford^{3,4,5}, Tobias Deschner^{28,29}, Ariane Dux^{1,2}, Luke Edwards⁷, Cornelius Eichner⁶, Géraldine Escoubas²⁹, Malak Ettaj²⁹, Pawel Fedurek^{19,30}, Karina

Flores¹⁵, Richard Francke³¹, Angela D. Friederici⁶, Cédric Girard-Buttoz^{3,4,5}, Jorge Gomez Fortun^{1,5}, Zoro Bertin GoneBi^{5,32}, Tobias Gräßle¹, Eva Gruber-Dujardin¹⁸, Philipp Gunz¹¹, Jess Hartel^{33,34}, Daniel B. M. Haun¹⁰, Michael Henshall³⁵, Catherine Hobaiter^{19,36}, Noémie Hofman⁵, Jenny E. Jaffe^{1,5}, Carsten Jäger^{7,8}, Anna Jauch⁷, Stomy Kahemere³⁷, Evgeniya Kirilina^{7,9}, Robert Klopffleisch³⁸, Tobias Knauf-Witzens³⁹, Kathrin S. Kopp¹⁰, Guy Landry Mamboundou Kouima^{29,40}, Bastian Lange⁴¹, Kevin Langergraber^{17,42}, Arne Lawrenz⁴³, Fabian H. Leendertz^{1,2}, Ilona Lipp⁷, Matys Liptovszky⁴⁴, Tobias Loubser Theron³⁵, Christelle Patricia Lumbu³⁷, Patrice Makouloutou Nzassi⁴⁰, Kerstin Mätz-Rensing¹⁸, Richard McElreath⁴, Matthew McLennan⁴⁵, Zoltan Mezö⁴⁶, Sophie Moittie⁴⁴, Torsten Møller⁴⁷, Markus Morawski^{7,8}, David Morgan^{48,49}, Timothy Mugabe^{19,50}, Martin Muller^{33,51}, Matthias Müller⁵², Inoussa Njumboket²⁰, Karin Olofsson-Sannö⁵³, Alain Ondzie⁵⁴, Emily Otali³³, Michael Paquette⁷, Simone Pika^{28,29}, Kerrin Pine⁷, Andrea Pizarro¹⁵, Kamilla Pléh^{1,5}, Jessica Rendel⁴⁴, Sandra Reichler-Danielowski⁵⁵, Martha M. Robbins^{56,57}, Alejandra Romero Forero¹⁵, Konstantin Ruske⁵⁸, Liran Samuni^{5,59}, Crickette Sanz^{49,60}, André Schüle⁶¹, Ingo Schwabe²⁴, Katarina Schwalm²⁴, Sheri Speede⁶², Lara Southern^{28,29}, Jonas Steiner^{1,5}, Marc Stidworthy⁶³, Martin Surbeck^{59,64}, Claudia Szentiks⁴⁶, Tanguy Tanga^{29,40}, Reiner Ulrich⁶⁵, Steve Unwin⁶⁶, Erica van de Waal^{35,67}, Sue Walker⁶⁸, Nikolaus Weiskopf^{7,12}, Gudrun Wibbelt⁴⁶, Roman M. Wittig^{3,4,5}, Kim Wood⁶⁹, Klaus Zuberbühler^{19,70}

¹⁴Zoo Halle Zoo, Halle/Saale, GER; ¹⁵Tacugama Chimpanzee Sanctuary, Freetown, SLE; ¹⁶Makerere University, Kampala, UGA; ¹⁷Ngogo Chimpanzee Project, Kibale NP, UGA; ¹⁸German Primate Center, Göttingen, GER; ¹⁹Budongo Conservation Field Station, Masindi, UGA; ²⁰WWF DRC, Kinshasa, DRC; ²¹University of Michigan University, Ann Arbor, MI, USA; ²²Capuchins at Taboga, CRC; ²³Lola Ya Bonobo Sanctuary, Kinshasa, DRC; ²⁴Chemisches und Veterinäruntersuchungsamt Stuttgart, Fellbach, GER; ²⁵Zoo Leipzig, Leipzig, GER; ²⁶Alfred-Wegener-Institut, Helmholtz-Zentrum für Polar- und Meeresforschung, Bremerhaven, GER; ²⁷Veterinary Pathology and Preclinical Sciences, University of Liverpool, UK; ²⁸University of Osnabrück, Osnabrück, GER; ²⁹Ozouga Chimpanzee Project, Lonago NP, GAB; ³⁰Stirling University, Stirling, UK; ³¹Zoo Saarbrücken, Saarbrücken, GER; ³²University Felix Houphouët-Boigny, Abidjan, Ivory Coast; ³³Kibale Chimpanzee Project, Makerere University, UGA; ³⁴University of North Georgia, USA; ³⁵Inkawu Vervet Project, Mawana Game Reserve, KaZulu-Natal, RSA; ³⁶University of St. Andrews, St. Andrews, UK; ³⁷Institut National de Recherche Biomedicale, Kinshasa, DRC; ³⁸Institute of Veterinary Pathology, Freie Universität Berlin, GER; ³⁹Wilhelma, Stuttgart, GER; ⁴⁰Institut de Recherche en Ecologie Tropicale, Libreville, GAB; ⁴¹Zoo Bremerhaven, Bremerhaven, GER; ⁴²Arizona State University, Phoenix, USA; ⁴³Zoo Wuppertal, Wuppertal, GER; ⁴⁴Twycross Zoo, Little Orton, UK; ⁴⁵Bulindi Chimpanzee and Community Project, Hoima, UGA; ⁴⁶Leibniz Institute for Zoo and Wildlife Research, Berlin, GER; ⁴⁷Kolmarden Zoo, Stockholm, SWE; ⁴⁸Lincoln Park Zoo, Chicago, USA; ⁴⁹Goulougo Triangle Chimpanzee Project, CGO; ⁵⁰Veterinary Program, Uganda Wildlife Authority, UGA; ⁵¹University of New Mexico, Albuquerque, USA; ⁵²Bayerisches Landesamt für

Gesundheit und Lebensmittelsicherheit, Erlangen, GER; ⁵³National Veterinary Institute, Uppsala, Sweden; ⁵⁴Wildlife Conservation Society DR Congo, Kinshasa, DRC; ⁵⁵Zoo Heidelberg, Heidelberg, GER; ⁵⁶Department of Primatology, MPI EVA, GER; ⁵⁷Loango Gorilla Project, Loango NP, Gabon; ⁵⁸Zoo Magdeburg, Magdeburg, GER; ⁵⁹Harvard University, Cambridge, USA; ⁶⁰Washington University, St-Louis, USA; ⁶¹Zoo Berlin, Berlin, GER; ⁶²Sanaga Yong Sanctuary, CMR; ⁶³International Zoo Veterinary Group, Keighley, UK; ⁶⁴Kokolopori Bonobo Research Project, DRC; ⁶⁵Veterinary Medicine, University of Leipzig, GER; ⁶⁶Wildlife Health Australia, Sydney, AUS; ⁶⁷University of Lausanne, Lausanne, CH; ⁶⁸Chester Zoo, Chester, UK; ⁶⁹Welsh Mountain Zoo, Colwyn Bay, UK; ⁷⁰University of Neuchatel, Neuchatel, CH.

ORCID

Tobias Gräßle  <https://orcid.org/0000-0001-9103-3139>
 Catherine Crockford  <https://orcid.org/0000-0001-6597-5106>
 Cornelius Eichner  <https://orcid.org/0000-0001-5611-6748>
 Cédric Girard-Buttoz  <https://orcid.org/0000-0003-1742-4400>
 Carsten Jäger  <https://orcid.org/0000-0001-6512-9903>
 Evgeniya Kirilina  <https://orcid.org/0000-0003-1304-4363>
 Ilona Lipp  <https://orcid.org/0000-0002-5644-2057>
 Ariane Dux  <https://orcid.org/0000-0003-1819-8556>
 Luke Edwards  <https://orcid.org/0000-0002-8320-7298>
 Anna Jauch  <https://orcid.org/0000-0002-0771-3084>
 Kathrin S. Kopp  <https://orcid.org/0000-0002-8414-3193>
 Michael Paquette  <https://orcid.org/0000-0002-8917-3391>
 Kerrin Pine  <https://orcid.org/0000-0002-2486-2970>
 Daniel B. M. Haun  <https://orcid.org/0000-0002-3262-645X>
 Richard McElreath  <https://orcid.org/0000-0002-0387-5377>
 Alfred Anwander  <https://orcid.org/0000-0002-4861-4808>
 Philipp Gunz  <https://orcid.org/0000-0002-2350-4450>
 Markus Morawski  <https://orcid.org/0000-0002-3817-5186>
 Angela D. Friederici  <https://orcid.org/0000-0002-6328-865X>
 Nikolaus Weiskopf  <https://orcid.org/0000-0001-5239-1881>
 Fabian H. Leendertz  <https://orcid.org/0000-0002-2169-7375>
 Roman M. Wittig  <https://orcid.org/0000-0001-6490-4031>

REFERENCES

- Alkemade, A., Pine, K., Kirilina, E., Keuken, M. C., Mulder, M. J., Balesar, R., Groot, J. M., Bleys, R. L. A. W., Trampel, R., Weiskopf, N., Herrler, A., Möller, H. E., Bazin, P.-L., & Forstmann, B. U. (2020). 7 tesla MRI followed by histological 3D reconstructions in whole-brain specimens. *Frontiers in Neuroanatomy*, 14, 536838. <https://www.frontiersin.org/article/10.3389/fnana.2020.536838>
- Andersson, J. L. R., Skare, S., & Ashburner, J. (2003). How to correct susceptibility distortions in spin-echo echo-planar images: Application to diffusion tensor imaging. *NeuroImage*, 20(2), 870–888. [https://doi.org/10.1016/S1053-8119\(03\)00336-7](https://doi.org/10.1016/S1053-8119(03)00336-7)
- Andersson, J. L. R., & Sotiropoulos, S. N. (2016). An integrated approach to correction for off-resonance effects and subject movement in diffusion MR imaging. *NeuroImage*, 125, 1063–1078. <https://doi.org/10.1016/j.neuroimage.2015.10.019>
- Atapour, N., Majka, P., Wolkowicz, I. H., Malamanova, D., Worthy, K. H., & Rosa, M. G. P. (2019). Neuronal distribution across the cerebral cortex of the marmoset monkey (*Callithrix jacchus*). *Cerebral Cortex*, 29(9), 3836–3863. <https://doi.org/10.1093/cercor/bhy263>
- Bandini, E., & Harrison, R. A. (2020). Innovation in chimpanzees. *Biological Reviews*, 95(5), 1167–1197. <https://doi.org/10.1111/brv.12604>
- Barton, R. A. (2012). Embodied cognitive evolution and the cerebellum. *Philosophical Transactions of the Royal Society B: Biological Sciences*, 367(1599), 2097–2107. <https://doi.org/10.1098/rstb.2012.0112>
- Bennett, A. J., Pierre, P. J., Wesley, M. J., Latzman, R., Schapiro, S. J., Marenco, M. C., Bradley, B. J., Sherwood, C. C., Mullholland, M. M., & Hopkins, W. D. (2021). Predicting their past: Machine language learning can discriminate the brains of chimpanzees with different early-life social rearing experiences. *Developmental Science*, 24(6), e13114. <https://doi.org/10.1111/desc.13114>
- Boesch, C. (1991). The effects of leopard predation on grouping patterns in Forest chimpanzees. *Behaviour*, 117(3/4), 220–242. <https://www.jstor.org/stable/4534940>
- Bogart, S. L., Bennett, A. J., Schapiro, S. J., Reamer, L. A., & Hopkins, W. D. (2014). Different early rearing experiences have long-term effects on cortical organization in captive chimpanzees (*Pan troglodytes*). *Developmental Science*, 17(2), 161–174.
- Brammerloh, M., Morawski, M., Friedrich, I., Reinert, T., Lange, C., Pelicon, P., Vavpetič, P., Jankuhn, S., Jäger, C., Alkemade, A., Balesar, R., Pine, K., Gavriilidis, F., Trampel, R., Reimer, E., Arendt, T., Weiskopf, N., & Kirilina, E. (2021). Measuring the iron content of dopaminergic neurons in substantia nigra with MRI relaxometry. *NeuroImage*, 239, 118255. <https://doi.org/10.1016/j.neuroimage.2021.118255>
- Bryant, K. L., & Preuss, T. M. (2018). A comparative perspective on the human temporal lobe. In E. Bruner, N. Ogiwara, & H. Tanabe (Eds.) *Digital endocasts. Replacement of neanderthals by modern humans series* (pp. 239–258). Springer. https://link.springer.com/chapter/10.1007/978-4-431-56582-6_16
- Buss, C., Entringer, S., Swanson, J. M., & Wadhwa, P. D. (2012). The role of stress in brain development: The gestational Environment's long-term effects on the brain. *Cerebrum: The Dana Forum on Brain Science*, 2012, 4. <https://www.ncbi.nlm.nih.gov/pmc/articles/PMC3574809/>
- Calvignac-Spencer, S., Leendertz, S. A. J., Gillespie, T. R., & Leendertz, F. H. (2012). Wild great apes as sentinels and sources of infectious disease. *Clinical Microbiology and Infection*, 18(6), 521–527. <https://doi.org/10.1111/j.1469-0691.2012.03816.x>
- Connor, R. C. (2007). Dolphin social intelligence: Complex alliance relationships in bottlenose dolphins and a consideration of selective environments for extreme brain size evolution in mammals. *Philosophical Transactions of the Royal Society B: Biological Sciences*, 362(1480), 587–602. <https://doi.org/10.1098/rstb.2006.1997>
- DeCasien, A. R., Williams, S. A., & Higham, J. P. (2017). Primate brain size is predicted by diet but not sociality. *Nature Ecology & Evolution*, 1, 0112. <https://doi.org/10.1038/s41559-017-0112>
- Eichner, C., Paquette, M., Mildner, T., Schlumm, T., Pléh, K., Samuni, L., Crockford, C., Wittig, R. M., Jäger, C., Möller, H. E., Friederici, A. D., & Anwander, A. (2020). Increased sensitivity and signal-to-noise ratio in diffusion-weighted MRI using multi-echo acquisitions. *NeuroImage*, 221, 117172. <https://doi.org/10.1016/j.neuroimage.2020.117172>
- Estrada, A., Garber, P. A., Rylands, A. B., Roos, C., Fernandez-Duque, E., Di Fiore, A., Nekaris, K. A.-I., Nijman, V., Heymann, E. W., Lambert, J. E., Rovero, F., Barelli, C., Setchell, J. M., Gillespie, T. R., Mittermeier, R. A., Arregoitia, L. V., de Guinea, M., Gouveia, S., Dobrovolski, R., ... Li, B. (2017). Impending extinction crisis of the world's primates: Why primates matter. *Science Advances*, 3(1), e1600946. <https://doi.org/10.1126/sciadv.1600946>
- Formenty, P., Boesch, C., Wyers, M., Steiner, C., Donati, F., Dind, F., Walker, F., & Le Guenno, B. (1999). Ebola virus outbreak among wild chimpanzees living in a rain Forest of Côte D'ivoire. *The Journal of Infectious Diseases*, 179(Supplement_1), S120–S126. <https://doi.org/10.1086/514296>

- Friedrich, P., Forkel, S. J., Amiez, C., Balsters, J. H., Coulon, O., Fan, L., Goulas, A., Hadj-Bouziane, F., Hecht, E. E., Heuer, K., Jiang, T., Latzman, R. D., Liu, X., Loh, K. K., Patil, K. R., Lopez-Persem, A., Procyk, E., Sallet, J., Toro, R., ... Thiebaut de Schotten, M. (2021). Imaging evolution of the primate brain: The next frontier? *NeuroImage*, 228, 117685. <https://doi.org/10.1016/j.neuroimage.2020.117685>
- Girard-Buttoz, C., Zaccarella, E., Bortolato, T., Friederici, A. D., Wittig, R. M., & Crockford, C. (2022). Chimpanzees produce diverse vocal sequences with ordered and recombinatorial properties. *Communications Biology*, 5(1), 1–15. <https://doi.org/10.1038/s42003-022-03350-8>
- González-Forero, M., & Gardner, A. (2018). Inference of ecological and social drivers of human brain-size evolution. *Nature*, 557(7706), 554–557. <https://doi.org/10.1038/s41586-018-0127-x>
- Grabinski, T. M., Kneynsberg, A., Manfredsson, F. P., & Kanaan, N. M. (2015). A method for combining RNAscope In situ hybridization with immunohistochemistry in thick free-floating brain sections and primary neuronal cultures. *PLoS ONE*, 10(3), e0120120. <https://doi.org/10.1371/journal.pone.0120120>
- Gudbjartsson, H., & Patz, S. (1995). The rician distribution of noisy MRI data. *Magnetic Resonance in Medicine*, 34(6), 910–914. <https://doi.org/10.1002/mrm.1910340618>
- Harvey, P. H., Clutton-Brock, T. H., & Mace, G. M. (1980). Brain size and ecology in small mammals and primates. *Proceedings of the National Academy of Sciences of the United States of America*, 77(7), 4387–4389. <https://doi.org/10.1073/pnas.77.7.4387>
- Hoekzema, E., Barba-Müller, E., Pozzobon, C., Picado, M., Lucco, F., García-García, D., Soliva, J. C., Tobeña, A., Desco, M., Crone, E. A., Ballesteros, A., Carmona, S., & Vilarroya, O. (2017). Pregnancy leads to long-lasting changes in human brain structure. *Nature Neuroscience*, 20(2), 287–296. <https://doi.org/10.1038/nn.4458>
- Hoffmann, C., Zimmermann, F., Biek, R., Kuehl, H., Nowak, K., Mundry, R., Agbor, A., Angedakin, S., Arandjelovic, M., Blankenburg, A., Brazzola, G., Corogenes, K., Couacy-Hymann, E., Deschner, T., Dieguez, P., Dierks, K., Düx, A., Dupke, S., Eshuis, H., ... Leendertz, F. H. (2017). Persistent anthrax as a major driver of wildlife mortality in a tropical rainforest. *Nature*, 548(7665), 82–86. <https://doi.org/10.1038/nature23309>
- IUCN. (n.d.). *The IUCN Red List of Threatened Species*. <https://www.iucnredlist.org/en>
- Iwaniuk, A. N. (2010). Comparative brain collections are an indispensable resource for evolutionary neurobiology. *Brain, Behavior and Evolution*, 76(2), 87–88. <https://doi.org/10.1159/000320214>
- Jerison, H. J. (1970). Brain evolution: New light on old principles. *Science*, 170(3963), 1224–1225. <https://doi.org/10.1126/science.170.3963.1224>
- Junker, J., Petrovan, S. O., Arroyo-Rodríguez, V., Boonratana, R., Byler, D., Chapman, C. A., Chetry, D., Cheyne, S. M., Cornejo, F. M., Cortés-Ortiz, L., Cowlshaw, G., Christie, A. P., Crockford, C., Torre, S. D. L., De Melo, F. R., Fan, P., Grueter, C. C., Guzmán-Caro, D. C., Heymann, E. W., ... Kühl, H. S. (2020). A severe lack of evidence limits effective conservation of the World's primates. *Bioscience*, 70(9), 794–803. <https://doi.org/10.1093/biosci/biaa082>
- Kaas, J. H., & van Eden, C. G. (2011). Brain banks provide a valuable resource for comparative studies. *Brain, Behavior and Evolution*, 77(2), 65–66. <https://doi.org/10.1159/000324526>
- Kellner, E., Dhital, B., Kiselev, V. G., & Reisert, M. (2016). Gibbs-ringing artifact removal based on local subvoxel-shifts. *Magnetic Resonance in Medicine*, 76(5), 1574–1581. <https://doi.org/10.1002/mrm.26054>
- Kenar, L., Ortatli, M., Yaren, H., Karayilanoglu, T., & Aydogan, H. (2007). Comparative sporidial effects of disinfectants after release of a biological agent. *Military Medicine*, 172(6), 616–621. <https://doi.org/10.7205/MILMED.172.6.616>
- Kopp, K. S., Ebel, S. J., Wittig, R. M., Haun, D. B. M., & Crockford, C. (2021). Small mirrors do the trick: A simple, but effective method to study mirror self-recognition in chimpanzees. *Animal Behavior and Cognition*, 8(3), 391–404. <https://doi.org/10.26451/abc.08.03.05.2021>
- Kori, S. (2018). Time since death from rigor mortis: Forensic prospective. *Journal of Forensic Sciences & Criminal Investigation*, 9(5), 555771. <https://doi.org/10.19080/JFSCI.2018.09.555771>
- Leendertz, F. H., Ellerbrok, H., Boesch, C., Couacy-Hymann, E., Mätz-Rensing, K., Hakenbeck, R., Bergmann, C., Abaza, P., Junglen, S., Moebius, Y., Vigilant, L., Formenty, P., & Pauli, G. (2004). Anthrax kills wild chimpanzees in a tropical rainforest. *Nature*, 430(6998), 451–452. <https://doi.org/10.1038/nature02722>
- Leendertz, F. H., Pauli, G., Maetz-Rensing, K., Boardman, W., Nunn, C., Ellerbrok, H., Jensen, S. A., Junglen, S., & Christophe, B. (2006). Pathogens as drivers of population declines: The importance of systematic monitoring in great apes and other threatened mammals. *Biological Conservation, Infectious Disease and Mammalian Conservation*, 131, 325–337. <https://doi.org/10.1016/j.biocon.2006.05.002>
- Lindenfors, P., Nunn, C. L., & Barton, R. A. (2007). Primate brain architecture and selection in relation to sex. *BMC Biology*, 5(1), 20. <https://doi.org/10.1186/1741-7007-5-20>
- Lipp, I., Kirilina, E., Edwards, L. J., Pine, K. J., Jäger, C., Gräßle, T., Consortium, E. B. C., Weiskopf, N., & Helms, G. (2022). B1+ correction of magnetization transfer saturation maps optimized for 7T postmortem MRI of the brain. *Magnetic Resonance in Medicine*. Online advance publication. <https://doi.org/10.1002/mrm.29524>
- Liu, C.-Q., Shan, L., Balesar, R., Luchetti, S., Van Heerikhuizen, J. J., Luo, J.-H., Swaab, D. F., & Bao, A.-M. (2010). A quantitative in situ hybridization protocol for formalin-fixed paraffin-embedded archival post-mortem human brain tissue. *Methods*, 52(4), 359–366. <https://doi.org/10.1016/j.ymeth.2010.07.004>
- Lothe, F. (1964). The use of larval infestation in determining time of death. *Medicine, Science and the Law*, 4(2), 113–115. <https://doi.org/10.1177/002580246400400207>
- Lutti, A., Hutton, C., Finsterbusch, J., Helms, G., & Weiskopf, N. (2010). Optimization and validation of methods for mapping of the radiofrequency transmit field at 3T. *Magnetic Resonance in Medicine*, 64(1), 229–238. <https://doi.org/10.1002/mrm.22421>
- Lutti, A., Stadler, J., Josephs, O., Windischberger, C., Speck, O., Bernarding, J., Hutton, C., & Weiskopf, N. (2012). Robust and fast whole brain mapping of the RF transmit field B1 at 7T. *PLoS One*, 7(3), e32379. <https://doi.org/10.1371/journal.pone.0032379>
- Maguire, E. A., Gadian, D. G., Johnsrude, I. S., Good, C. D., Ashburner, J., Frackowiak, R. S., & Frith, C. D. (2000). Navigation-related structural change in the hippocampi of taxi drivers. *Proceedings of the National Academy of Sciences of the United States of America*, 97(8), 4398–4403. <https://doi.org/10.1073/pnas.070039597>
- Mai, J. K., Assheuer, J., & Paxinos, G. (2004). *Atlas of the human brain*, (2004). Elsevier Academic Press.
- Margiotoudi, K., Marie, D., Claidière, N., Coulon, O., Roth, M., Nazarian, B., Lacoste, R., Hopkins, W. D., Molesti, S., Fresnais, P., Anton, J.-L., & Meguerditchian, A. (2019). Handedness in monkeys reflects hemispheric specialization within the central sulcus. An in vivo MRI study in right- and left-handed olive baboons. *Cortex*, 118, 203–211. <https://doi.org/10.1016/j.cortex.2019.01.001>
- Martin, C. (2014). Contributions and complexities from the use of in vivo animal models to improve understanding of human neuroimaging signals. *Frontiers in Neuroscience*, 8, 211. <https://www.frontiersin.org/article/10.3389/fnins.2014.00211>
- Meguerditchian, A., Marie, D., Margiotoudi, K., Roth, M., Nazarian, B., Anton, J.-L., & Claidière, N. (2021). Baboons (*Papio anubis*) living in larger social groups have bigger brains. *Evolution and Human Behavior*, 42(1), 30–34. <https://doi.org/10.1016/j.evolhumbehav.2020.06.010>
- Miguel, P. M., Pereira, L. O., Silveira, P. P., & Meaney, M. J. (2019). Early environmental influences on the development of children's brain structure and function. *Developmental Medicine & Child Neurology*, 61(10), 1127–1133. <https://doi.org/10.1111/dmnc.14182>

- Miller, D. J., Duka, T., Stimpson, C. D., Schapiro, S. J., Baze, W. B., McArthur, M. J., Fobbs, A. J., Sousa, A. M. M., Šestan, N., Wildman, D. E., Lipovich, L., Kuzawa, C. W., Hof, P. R., & Sherwood, C. C. (2012). Prolonged myelination in human neocortical evolution. *Proceedings of the National Academy of Sciences of the United States of America*, 109(41), 16480–16485. <https://doi.org/10.1073/pnas.1117943109>
- Mubemba, B., Chanove, E., Mätz-Rensing, K., Gogarten, J. F., Düx, A., Merkel, K., Röthemeier, C., Sachse, A., Rase, H., Humle, T., Banville, G., Tchoubar, M., Calvignac-Spencer, S., Colin, C., & Leendertz, F. H. (2020). Yaws disease caused by *Treponema pallidum* subspecies pertenue in wild chimpanzee, Guinea, 2019. *Emerging Infectious Diseases*, 26(6), 1283–1286. <https://doi.org/10.3201/eid2606.191713>
- Mulholland, M. M., Sherwood, C. C., Schapiro, S. J., Raghanti, M. A., & Hopkins, W. D. (2021). Age- and cognition-related differences in the gray matter volume of the chimpanzee brain (pan troglodytes): A voxel-based morphometry and conjunction analysis. *American Journal of Primatology*, 83(11), e23264. <https://doi.org/10.1002/ajp.23264>
- National Chimpanzee Brain Resource (RRID:SCR_019183). (n.d.). <http://www.chimpanzeebrain.org/>
- Padrell, M., Llorente, M., & Amici, F. (2021). Invasive research on non-human primates—Time to turn the page. *Animals*, 11(10), 2999. <https://doi.org/10.3390/ani11102999>
- Patrono, L. V., Pléh, K., Samuni, L., Ulrich, M., Röthemeier, C., Sachse, A., Muschter, S., Nitsche, A., Couacy-Hymann, E., Boesch, C., Wittig, R. M., Calvignac-Spencer, S., & Leendertz, F. H. (2020). Monkeypox virus emergence in wild chimpanzees reveals distinct clinical outcomes and viral diversity. *Nature Microbiology*, 5(7), 955–965. <https://doi.org/10.1038/s41564-020-0706-0>
- Pope, S. M., Tagliabata, J. P., Skiba, S. A., & Hopkins, W. D. (2018). Changes in frontoparietotemporal connectivity following do-As-I-do imitation training in chimpanzees (*pan troglodytes*). *Journal of Cognitive Neuroscience*, 30(3), 421–431. Scopus. https://doi.org/10.1162/jocn_a_01217
- Powell, L. E., Isler, K., & Barton, R. A. (2017). Re-evaluating the link between brain size and behavioural ecology in primates. *Proceedings of the Royal Society B: Biological Sciences*, 284(1865), 20171765. <https://doi.org/10.1098/rspb.2017.1765>
- Quallo, M. M., Price, C. J., Ueno, K., Asamizuya, T., Cheng, K., Lemon, R. N., & Iriki, A. (2009). Gray and white matter changes associated with tool-use learning in macaque monkeys. *Proceedings of the National Academy of Sciences of the United States of America*, 106(43), 18379–18384.
- Reader, S. M., & Laland, K. N. (2002). Social intelligence, innovation, and enhanced brain size in primates. *Proceedings of the National Academy of Sciences of the United States of America*, 99(7), 4436–4441.
- Reddon, A. R., Chouinard-Thuly, L., Leris, I., & Reader, S. M. (2018). Wild and laboratory exposure to cues of predation risk increases relative brain mass in male guppies. *Functional Ecology*, 32(7), 1847–1856. <https://doi.org/10.1111/1365-2435.13128>
- Rilling, J. K., Glasser, M. F., Preuss, T. M., Ma, X., Zhao, T., Hu, X., & Behrens, T. E. (2008). The evolution of the arcuate fasciculus revealed with comparative DTI. *Nature Neuroscience*, 11(4), 426–428. <https://doi.org/10.1038/nn2072>
- Sakai, T., Matsui, M., Mikami, A., Malkova, L., Hamada, Y., Tomonaga, M., Suzuki, J., Tanaka, M., Miyabe-Nishiwaki, T., Makishima, H., Nakatsukasa, M., & Matsuzawa, T. (2013). Developmental patterns of chimpanzee cerebral tissues provide important clues for understanding the remarkable enlargement of the human brain. *Proceedings of the Biological Sciences*, 280(1753), 20122398. <https://doi.org/10.1098/rspb.2012.2398>
- Sallet, J., Mars, R. B., Noonan, M. P., Andersson, J. L., O'Reilly, J. X., Jbabdi, S., Croxson, P. L., Jenkinson, M., Miller, K. L., & Rushworth, M. F. S. (2011). Social network size affects neural circuits in macaques. *Science*, 334(6056), 697–700. <https://doi.org/10.1126/science.1210027>
- Saraf, M. P., Balaram, P., Pifferi, F., Gămănuț, R., Kennedy, H., & Kaas, J. H. (2019). Architectonic features and relative locations of primary sensory and related areas of neocortex in mouse lemurs. *Journal of Comparative Neurology*, 527(3), 625–639. <https://doi.org/10.1002/cne.24419>
- Schubert, M. I., Porkess, M. V., Dashdorj, N., Fone, K. C. F., & Auer, D. P. (2009). Effects of social isolation rearing on the limbic brain: A combined behavioral and magnetic resonance imaging volumetry study in rats. *Neuroscience*, 159(1), 21–30. <https://doi.org/10.1016/j.neuroscience.2008.12.019>
- Shultz, S., & Dunbar, R. I. M. (2007). The evolution of the social brain: Anthropoid primates contrast with other vertebrates. *Proceedings of the Royal Society B: Biological Sciences*, 274(1624), 2429–2436. <https://doi.org/10.1098/rspb.2007.0693>
- Skeide, M. A., & Friederici, A. D. (2016). The ontogeny of the cortical language network. *Nature Reviews Neuroscience*, 17(5), 323–332. <https://doi.org/10.1038/nrn.2016.23>
- Sol, D., Bacher, S., Reader, S. M., & Lefebvre, L. (2008). Brain size predicts the success of mammal species introduced into novel environments. *The American Naturalist*, 172(S1), S63–S71. <https://doi.org/10.1086/588304>
- Tabelow, K., Balteau, E., Ashburner, J., Callaghan, M. F., Draganski, B., Helms, G., Kherif, F., Leutritz, T., Lutti, A., Phillips, C., Reimer, E., Ruthotto, L., Seif, M., Weiskopf, N., Ziegler, G., & Mohammadi, S. (2019). HMRI – A toolbox for quantitative MRI in neuroscience and clinical research. *NeuroImage*, 194, 191–210. <https://doi.org/10.1016/j.neuroimage.2019.01.029>
- Triki, Z., Levorato, E., McNeely, W., Marshall, J., & Bshary, R. (2019). Population densities predict forebrain size variation in the cleaner fish *Labroides dimidiatus*. *Proceedings of the Royal Society B: Biological Sciences*, 286(1915), 20192108. <https://doi.org/10.1098/rspb.2019.2108>
- Tsokos, M., & Byard, R. W. (2012). Putrefactive “rigor mortis”. *Forensic Science, Medicine, and Pathology*, 8(2), 200–201. <https://doi.org/10.1007/s12024-011-9232-y>
- Veraart, J., Novikov, D. S., Christiaens, D., Ades-aron, B., Sijbers, J., & Fieremans, E. (2016). Denoising of diffusion MRI using random matrix theory. *NeuroImage*, 142, 394–406. <https://doi.org/10.1016/j.neuroimage.2016.08.016>
- Vijayakumar, N., Op de Macks, Z., Shirtcliff, E. A., & Pfeifer, J. H. (2018). Puberty and the human brain: Insights into adolescent development. *Neuroscience & Biobehavioral Reviews*, 92, 417–436. <https://doi.org/10.1016/j.neubiorev.2018.06.004>
- Vos, S. B., Tax, C. M. W., Luijten, P. R., Ourselin, S., Leemans, A., & Froeling, M. (2017). The importance of correcting for signal drift in diffusion MRI. *Magnetic Resonance in Medicine*, 77, 285–299. <https://doi.org/10.1002/mrm.26124>
- Weiskopf, N., Edwards, L. J., Helms, G., Mohammadi, S., & Kirilina, E. (2021). Quantitative magnetic resonance imaging of brain anatomy and in vivo histology. *Nature Reviews Physics*, 3(8), 570–588. <https://doi.org/10.1038/s42254-021-00326-1>
- Weiskopf, N., Mohammadi, S., Lutti, A., & Callaghan, M. F. (2015). Advances in MRI-based computational neuroanatomy: From morphometry to in-vivo histology. *Current Opinion in Neurology*, 28(4), 313–322. <https://doi.org/10.1097/WCO.0000000000000222>
- Whiten, A., Goodall, J., McGrew, W. C., Nishida, T., Reynolds, V., Sugiyama, Y., Tutin, C. E., Wrangham, R. W., & Boesch, C. (1999). Cultures in chimpanzees. *Nature*, 399(6737), 682–685.
- Wilson, M. L., Boesch, C., Fruth, B., Furuichi, T., Gilby, I. C., Hashimoto, C., Hobaier, C. L., Hohmann, G., Itoh, N., Koops, K., Lloyd, J. N., Matsuzawa, T., Mitani, J. C., Mjungu, D. C., Morgan, D., Muller, M. N., Mundry, R., Nakamura, M., Pruetz, J., ... Wrangham, R. W. (2014). Lethal aggression in pan is better explained by adaptive strategies than human impacts. *Nature*, 513(7518), 414–417. <https://doi.org/10.1038/nature13727>

- Wittig, R. M., & Boesch, C. (2019). Observation protocol and long-term data collection in Tai. In C. Boesch, & R. M. Wittig (Eds.) *The tai chimpanzees: 40 years of research* (pp. 44–57). Cambridge University Press.
- Zhou, C., & Byard, R. W. (2011). Factors and processes causing accelerated decomposition in human cadavers – An overview. *Journal of Forensic and Legal Medicine*, 18(1), 6–9. <https://doi.org/10.1016/j.jflm.2010.10.003>

SUPPORTING INFORMATION

Additional supporting information can be found online in the Supporting Information section at the end of this article.

How to cite this article: Gräßle, T., Crockford, C., Eichner, C., Girard-Buttoz, C., Jäger, C., Kirilina, E., Lipp, I., Dux, A., Edwards, L., Jauch, A., Kopp, K. S., Paquette, M., Pine, K., Haun, D. B. M., McElreath, R., Anwender, A., Gunz, P., Morawski, M., Friederici, A. D. ... (2023). Sourcing high tissue quality brains from deceased wild primates with known socio-ecology. *Methods in Ecology and Evolution*, 00, 1–19. <https://doi.org/10.1111/2041-210X.14039>